

How should I treat my Parkinson's disease?

Katerina Markopoulou, MD, PhD

Staff Neurologist

NorthShore University HealthSystem

Clinical Assistant Professor

University of Chicago

Parkinson's disease therapy

- Medical management
- Surgical management

Medications used in the treatment of Parkinson's disease

Dopamine agonists	MAO-B inhibitors	COMT inhibitors	Anticholinergics
Pramipexole (mirapex) Immediate and extended release	Selegiline	Entacapone (comtan)	Trihexyphenidyl (artane)
Ropinirole (requip) Immediate and extended release	Rasagiline (Azilect)	Tolcapone (tasmar)	Benzotropine (Cogentin)
Rotigotine (Neupro) patch			
Apomorphine (Apokyn) Subcutaneous injection			

Levodopa

Levodopa remains the cornerstone of medical therapy for the last 50 years

Currently available formulations:

carbidopa/levodopa Immediate Release (IR)
10/100; 25/100; 25/250

carbidopa/levodopa Controlled release (CR)
50/200; 25/100

carbidopa/levodopa Orally disintegrating (ODT)
(Parcopa)

carbidopa/levodopa with entacapone (Stalevo)
50, 75, 100, 125, 150, 200

Non-motor manifestations of Parkinson's disease

- Blood pressure fluctuations
 - Fludrocortisone
 - Midodrine
 - Droxidopa (recent FDA approval)
- Urinary incontinence
 - Oxybutynin (ditropan)
 - Solifenacin (vesicare)
 - Trospium (sanctura)
 - Darifenacin (enablex)
 - Tolterodine (Detrol LA)
- Sleep disturbances
 - Clonazepam
 - Long acting dopaminergic medications
- Smell loss
 - no treatment available

Non-motor manifestations of Parkinson's disease

Anxiety and depression

- sertraline (zoloft)
- venlafaxine (effexor)
- escitalopram (lexapro)
- citalopram (celexa)

Cognitive abnormalities

- Rivastigmine (exelon)
- Memantine (namenda)

Behavioral manifestations

Hallucinations

Paranoid thinking

Agitation

- Clozapine (Clozaril)
 - Effective but requires weekly blood tests
- Quetiapine (Seroquel)

Medications **to be avoided** in Parkinson's disease

Haloperidol (Haldol)

Risperidone (Risperidal)

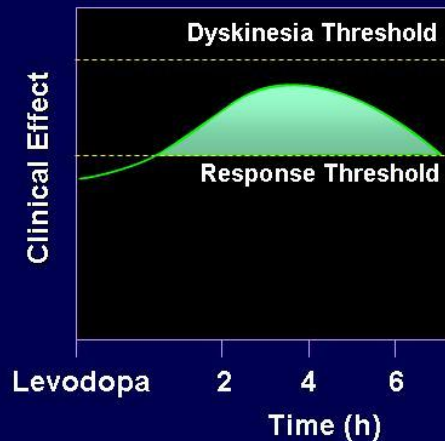
Olanzapine (Zyprexa)

Metoclopramide (Reglan)

Compazine

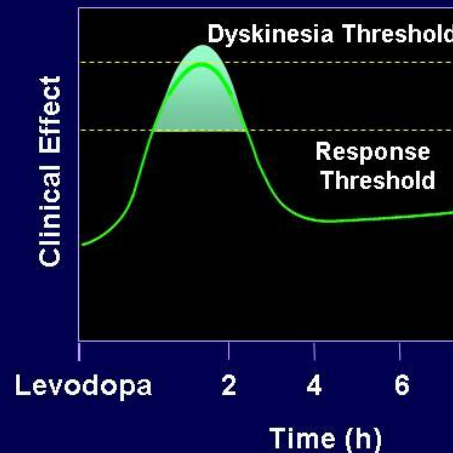
Response to Levodopa and Progression of Parkinson's Disease

Early PD



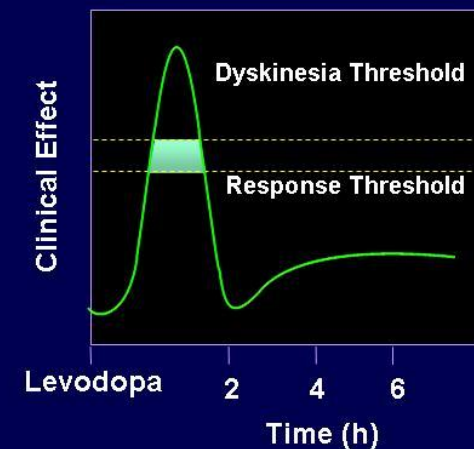
- Long duration motor response
- Low incidence of dyskinesias

Moderate PD



- Shorter duration motor response
- Increased incidence of dyskinesias

Advanced PD



- Short duration motor response
- "On" time consistently associated with dyskinesias

Complications of levodopa therapy

- Motor fluctuations
 - Delayed “ON” response
 - Dose failure
 - End-of-dose wearing-Off
 - Unpredictable “OFF” time
 - Freezing episodes

Complications of levodopa therapy

- Dyskinesias (involuntary “wiggly” movements)
 - peak dose (30-60 minutes after a dose)
 - biphasic (occur twice in a dosing interval)
 - continuous (30 minutes after dose and lasting until next dose)

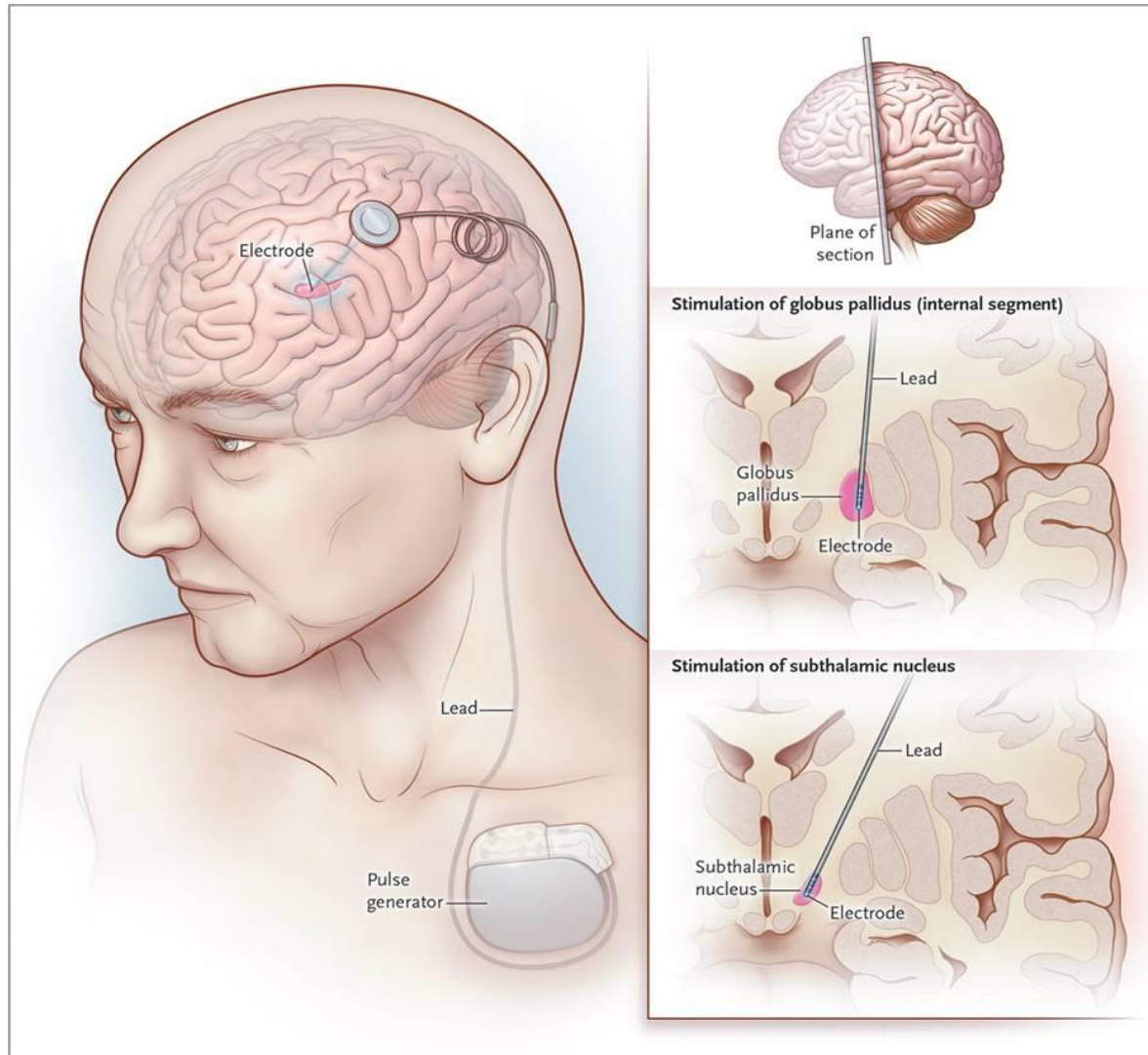
Surgical Treatments for Parkinson's Disease

- Ablative procedures
 - thalamotomy
 - pallidotomy
- Electrical stimulation procedures (DBS)
 - globus pallidus internus
 - subthalamic nucleus

Deep Brain Stimulation (DBS)

- High frequency electrical stimulation
- Stimulating electrodes are stereotactically placed into target nucleus
- Can be activated and deactivated with an external magnet
- The patient has the option of adjusting stimulation parameters.
- Exact mechanism is unknown, but higher stimulation frequencies mimic ablation

DBS targets



Surgical Candidate Selection

- Disease duration > 5 years
- Confirmed diagnosis of Parkinson's Disease
- Complications of optimal medical therapy
- Continued good response to levodopa
- Absence of dementia
- Absence of depression
- Ability to tolerate surgical procedure

Contraindications to surgical treatment

Blood clotting disorders

Poorly controlled hypertension

Overall compromised health status

- pacemaker

Subthalamic nucleus DBS

- All cardinal features of PD noted to improve
- “Off” time improved 60%
- “On” time improved 10%
- Increased “on” time
- Reduced dyskinesias
- Reduced medication requirements

Subthalamic nucleus DBS

- Bilateral electrode placement is necessary
- Unilateral placement may be considered in select cases
- Indicated for control of rigidity, bradykinesia and dyskinesias

DBS surgery timing

- DBS has been an established treatment for advanced Parkinson's disease.
- A recent large clinical trial published in 2013 (EARLYSTIM trial) supports surgery earlier in the disease process.
- Study participants with levodopa-induced complications had better quality of life and less motor disability than those that received medical therapy only

Timing of Surgery

- Are parkinsonian symptoms adequately treated?
- Is antiparkinsonian regimen optimized?
- Is DBS neuroprotective?

Effects of STN DBS

	STN
Tremor	+++
Bradykinesia	+++
Rigidity	+++
Gait	+++
Dyskinesias	- /+
Medication reduction	+++

Symptom change after turning on stimulation

Symptom	Sec.	Min.	Days	Wk/Mo
Rigidity	+++	S	S	S
Tremor	+++	+	(+)	(+)
Bradykinesia/akinesia	+++	+	+	S
Off-phase dystonias	++	+	+	S
Diphasic dyskinesias	(-)	-, (+)	++	+
On-period dyskinesia	(-)	--	-	++

+ = improvement; - , worsening s, stable

MRI safety guidelines

- MRI field strength: 1.5 Tesla
- MRI type: horizontal bore, not open-sided systems
- DBS leads and extensions should be intact and functional (needs to be checked prior to scan)

DBS-related Adverse Effects

Intracerebral hemorrhage

Seizures

Infection

Breaking of connection lead

Eyelid opening apraxia

Executive dysfunction

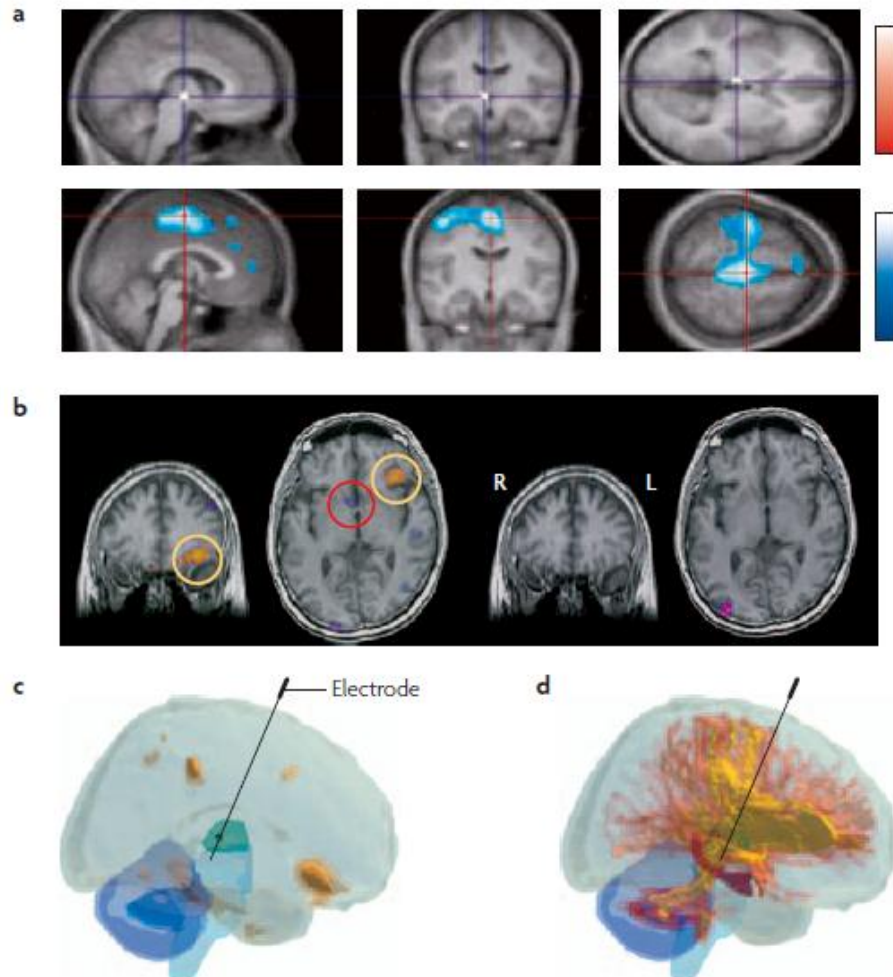
Confusion

Weight gain

DBS: how does it work?

- DBS mechanism continues to be a matter of debate
- Inhibition of the subthalamic nucleus
- Excitation of the subthalamic nucleus
- Combination of inhibition/excitation
- Modification of brain networks

Imaging of DBS effects



Summary

- DBS is effective in treating moderate to advanced PD
- Recent studies demonstrate that DBS is effective also early in the disease process
- Stimulation parameter adjustment can be useful to control symptoms effectively.

Experimental therapies

- Gene therapy trials
 - Recently published clinical trial in 15 individuals with advanced Parkinson's disease of gene therapy with genes involved in the processing of dopamine (Prosavin)
 - Treatment appears safe and well tolerated
 - Clinical improvement over a 12 month period was observed in all participants

Additional treatment options

- Continuous levodopa gel infusion in the gut (Duodopa)
- Currently in use in Europe
- Requires placement of a catheter in the duodenum
- Not enough information to compare its effectiveness with DBS therapy

Summary

- Parkinson's disease treatment is multifaceted and complex.
- Frequent monitoring and adjustment of treatment is necessary
- Treatment is individualized as the disease has a varied presentation and course.